

Surgery Illustrated – Surgical Atlas

Robot-assisted ascending-descending laparoscopic nerve-sparing prostatectomy

Rolf Gillitzer, Joachim W. Thüroff, Andreas Neisius, Jens Wöllner and Christian Hampel

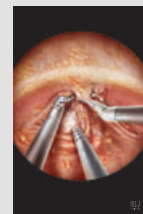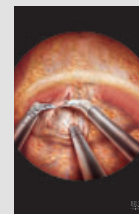
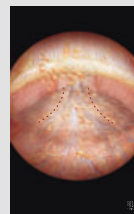
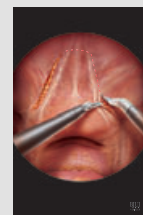
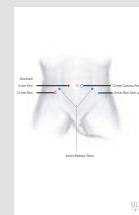

Department of Urology, University Medical Center, Johannes Gutenberg University, Mainz, Germany

ILLUSTRATIONS by STEPHAN SPITZER, www.spitzer-illustration.com

INTRODUCTION

Robot-assisted laparoscopic radical prostatectomy (RALP) has gained increasing popularity worldwide since its first description in 2000 [1]. The oncological and functional results are at least equivalent to those for radical retropubic prostatectomy (RP), which remains the reference standard [2]. The highly magnified stereoscopic vision in a bloodless operative field and excellent manoeuvrability of the articulated instruments are advantages that allow a precise and gentle dissection. The surgeon perceives anatomy from a different perspective with more details than he or she has been used to seeing in conventional open surgery, even with high power (×5) magnifying loupes. The natural intuitive movements at the console enable surgeons trained in RP to embark on minimally invasive surgery without having to undergo long and tedious training for conventional laparoscopic RP.

The techniques and results of nerve-sparing RALP have been described extensively [3–7]. In descending RALP, during preparation of the neurovascular bundles (NVBs), the prostate is held ventrally with the fourth arm or by the assistant, and the NVBs are swept away from the prostatic surface towards the rectum. However, larger vessels and a wider 'mesentery' of the cranial prostatic pedicle render identification of the prostatic capsule more difficult at this site than at the apex, where fewer vessels penetrate into the prostate. Moreover, in descending RP, another difficulty can arise when reaching the apical region. If the NVBs are tethered to the apex at this location, as might be the case in apical prostatic vessels [8], the exact plane of dissection can be difficult to identify and



injury to the tethered NVB might ensue. Rassweiler *et al.* [9] described a retrograde (ascending) technique for laparoscopic RP. We applied this principle to RALP, and noticed that identifying the correct plane between the prostatic capsule and the NVB is quite easy at the apex, and it allows for the expeditious progress of the procedure once the NVBs have been primarily identified.

The great dexterity obtainable with the articulated instruments is a key feature that simplifies completion of the vesicourethral anastomosis in a watertight and exact manner, using the parachute technique [10]. We describe nerve-sparing RALP as performed with the four arm da Vinci S system (Intuitive Surgical Inc, Sunnyvale, CA, USA).

PLANNING AND PREPARATION

RALP is indicated for treating localized prostate cancer in patients with a life expectancy of >10 years. A nerve-sparing procedure is performed according to hospital protocol. Our indication for bilateral nerve-sparing is stage T1c, Gleason score $\leq 7a$ (3 + 4) and a PSA level of ≤ 10 ng/mL. Unilateral

nerve-sparing is done on the contralateral side of a T2a stage, again with a Gleason score of $\leq 7a$ (3 + 4) and a PSA level of ≤ 10 ng/mL.

If applicable, the patient is instructed to stop antiplatelet agents and anticoagulant medication 1 week before the procedure or to change to s.c. heparin. The patient discontinues any oral intake and receives a laxative the night before the procedure. Antibiotic prophylaxis is begun at surgery with a third-generation cephalosporin.

SPECIFIC EQUIPMENT/MATERIALS

- da Vinci S system;
- 0° binocular telescope (additional 30° binocular telescope is advisable);
- Robotic instruments: Monopolar scissors, bipolar grasper (Maryland), Prograsp grasper, two large needle holders;
- Instruments for the assistant: long suction/irrigation device (5 mm, 18 inches Porges Elephant suction device, Coloplast, Denmark), grasper, disposable scissors;
- Curved Lowsely retractor;
- Trocars: 3 × 8 mm robotic trocars, 2 × 12 mm trocars, 1 × 5 mm trocar;

- Retrieval bag;
- Suture material:
 - 3/0 braided polyglycolic acid suture with a 5/8 needle (UR-6) for suturing the dorsal vein complex (20 cm);
 - 2/0 monofilament poliglecaprone suture with a 5/8 needle (UR-6) armed with a Lapra-Ty clip (Ethicon Endosurgery, Piscataway, NJ, USA) at the end (20 cm) for posterior reconstruction;
 - 2 × 2/0 monofilament poliglecaprone suture with a 5/8 needle (UR-6) armed with a Lapra-Ty clip at the end (20 cm each) joined together by a Hem-o-lok (Teleflex Medical, NC, USA) clip (large) for the vesicourethral anastomosis;
 - 2 × 2/0 monofilament poliglecaprone suture with a 5/8 needle (UR-6) armed with a Lapra-ty clip at the end (20 cm each) for bladder fixation to the abdominal wall;
- Clips: large (violet) and medium-large (green) nonabsorbable polymer Hem-o-lok clips; Lapra-Ty polydioxanone clips; titanium clips;
- Endoclose (Carter-Thomason device);
- Robotic pillow (Sampli Ind., Brakel, Belgium).

SURGICAL STEPS

Figure 1

SPECIFIC PATIENT POSITIONING &
SURGICAL TEAM

The patient is placed supine with the table flexed at the level of the hips. The legs are slightly abducted to allow for docking of the da Vinci surgical cart between the legs of the patient. The patient's legs are padded and securely fixed to the table. The patient rests on his shoulders on a specially designed soft cushioned pillow to prevent nerve compression injuries at the shoulder girdle. The patient's abdomen and genitals are scrubbed, and a Foley catheter is inserted. The assistant sits on the right side and the scrub nurse on the left side of the patient. Flat screen monitors are placed on both sides of the patient.

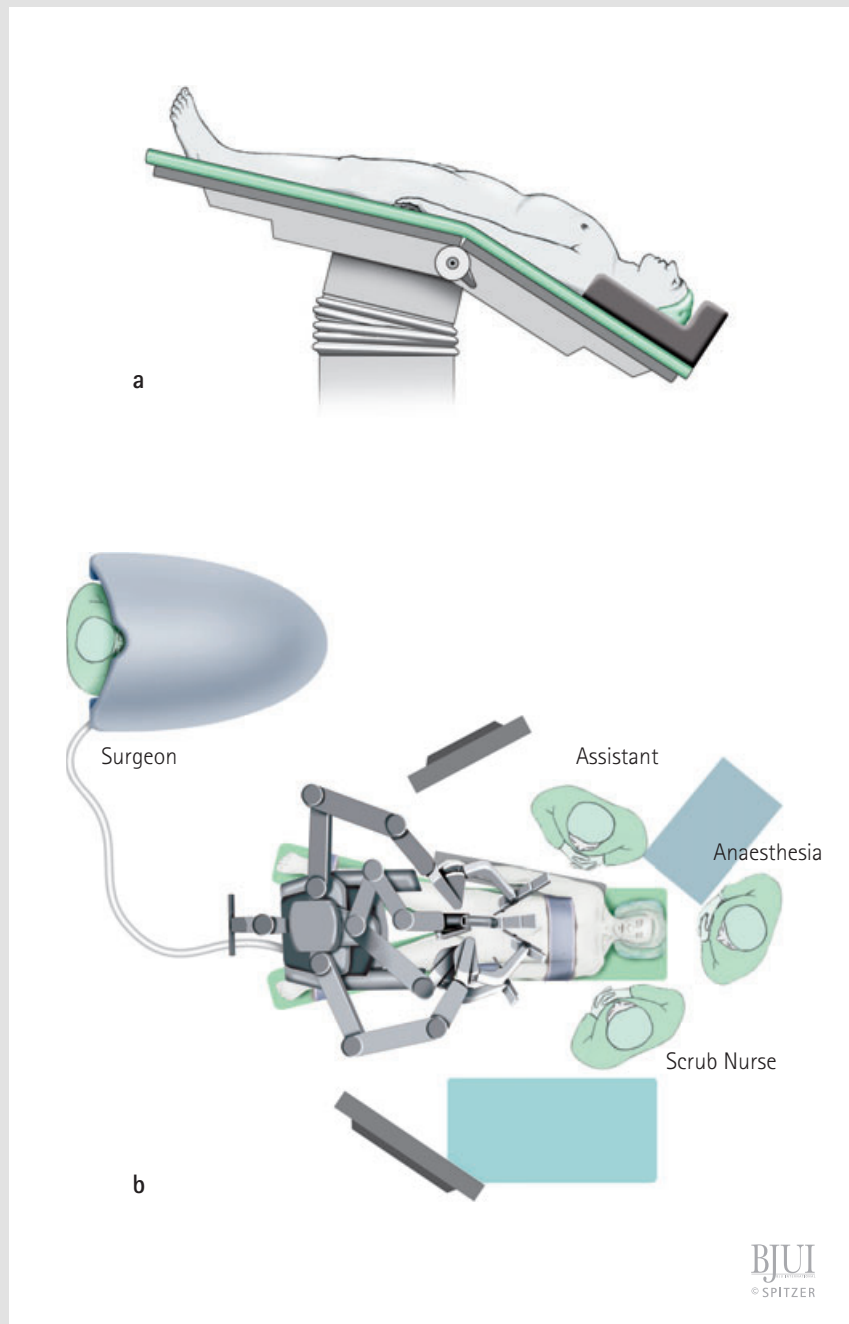


Figure 2**PORT PLACEMENT**

The camera port (12 mm) is placed lateral to the umbilicus on the left side or in a midline supra-umbilical position. Two robotic ports (8 mm) are placed pararectally on the left and on the right side ≈ 10 cm lateral and slightly more caudal to the camera port. A 5-mm assistant port (for suction/irrigation) is placed midway between the camera port and the right robotic port. A 12-mm assistant port is placed ≈ 3 cm from the iliac crest and slightly caudal to the right robotic port. This port allows introduction of needles and clip appliers. An 8-mm robotic port for the fourth arm is introduced in a mirror-like manner to the 12-mm assistant port on the left side. Final position of the ports shows a semicircular arrangement.

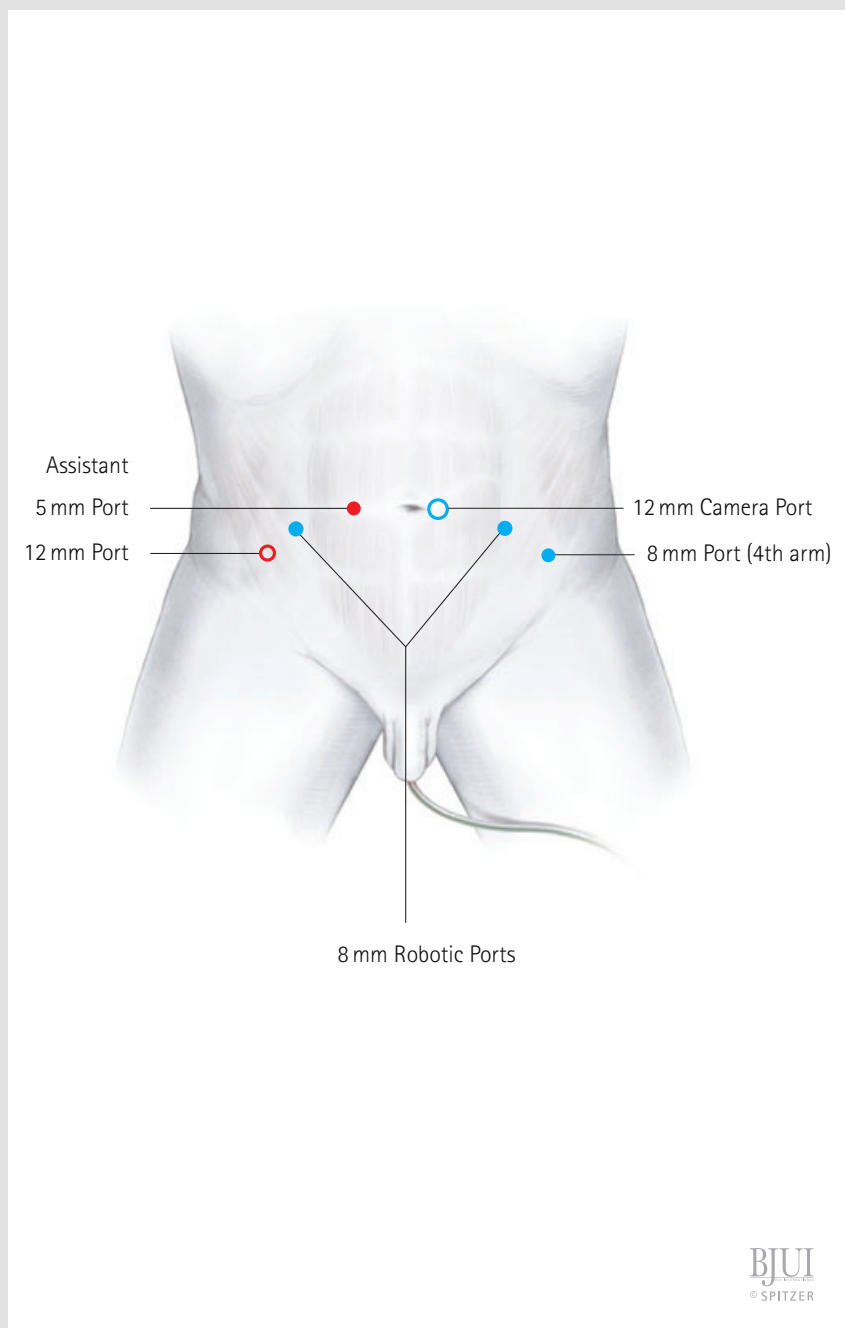


Figure 3

After establishing pneumoperitoneum with a Veress needle, the 12-mm optic trocar is introduced and the abdomen inspected. After placing the other ports the table is set in an extreme Trendelenburg position and the surgical robotic cart is docked to the ports. Routinely, the Maryland bipolar forceps are used with the left hand and the monopolar scissors with the right hand, as would be the case in open surgery for a right-handed surgeon. The bladder is mobilized from the anterior abdominal wall by incising the peritoneum lateral to the lateral umbilical ligament (obliterated umbilical artery) on both sides, beginning at the level of the crossing of the vas deferens. Incision of the peritoneum is followed ventrally towards the umbilicus, the bladder is mobilized from the abdominal wall by sharp and blunt dissection in the avascular plane of areolar connective tissue. Way above from the bladder dome, the lateral umbilical ligaments and the urachus are transected.

If pelvic lymphadenectomy is indicated, the incision of the peritoneum is continued along the external iliac artery towards the common iliac artery. It is advisable to identify the ureter crossing the iliac vessels to avoid inadvertent injury.

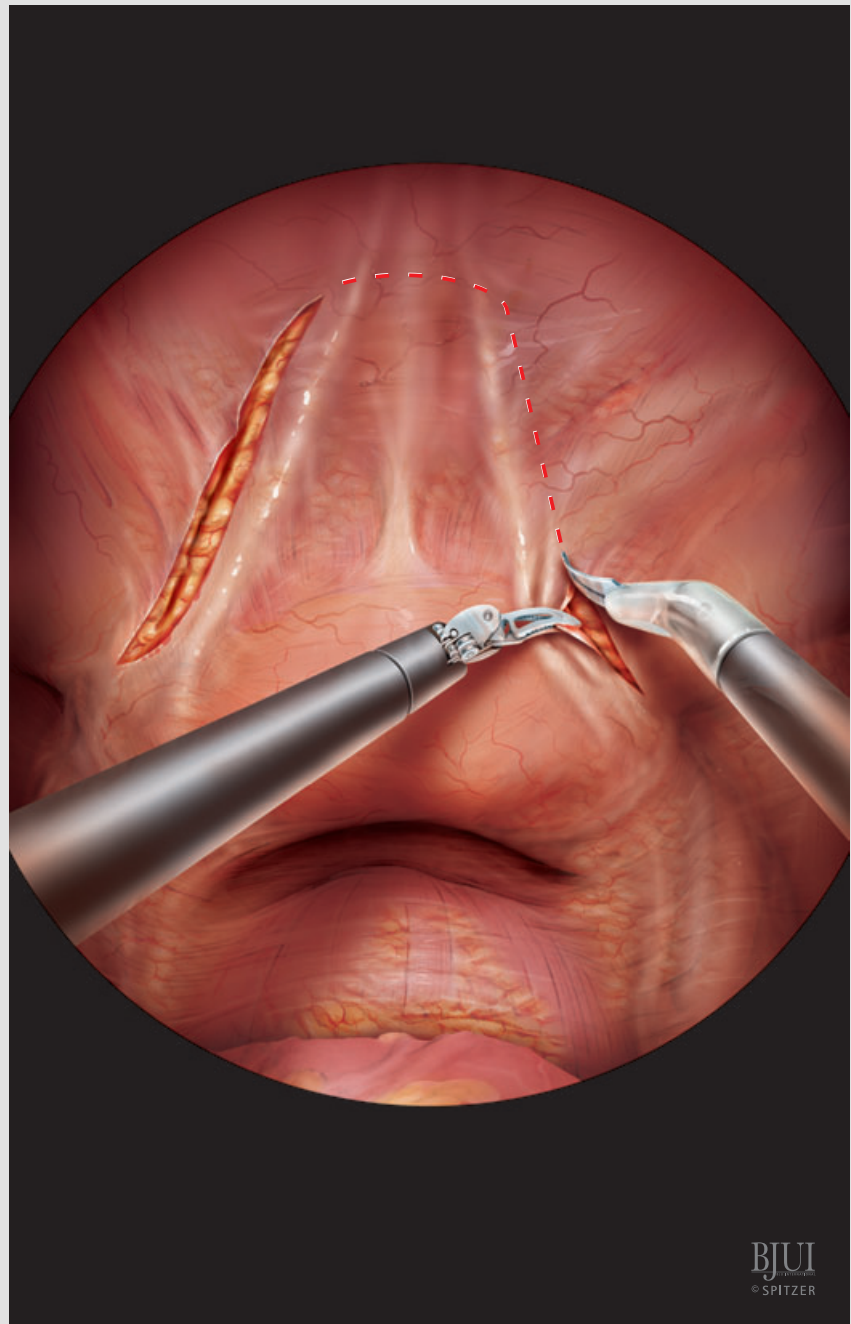


Figure 4

Once the bladder has been completely mobilized from the abdominal wall, the paravesical space lateral to the bladder is entered, exposing the endopelvic fascia by removing the overlying fat. The visceral layer of the endopelvic fascia (periprostatic fascia) is superficially incised at the 11 o'clock and 1 o'clock positions medial to the condensations of fascia that form the arcus tendineus, so that the prostate remains only at the ventral aspect covered by fascia and the parietal layer of the endopelvic fascia remains covering the levator musculature.

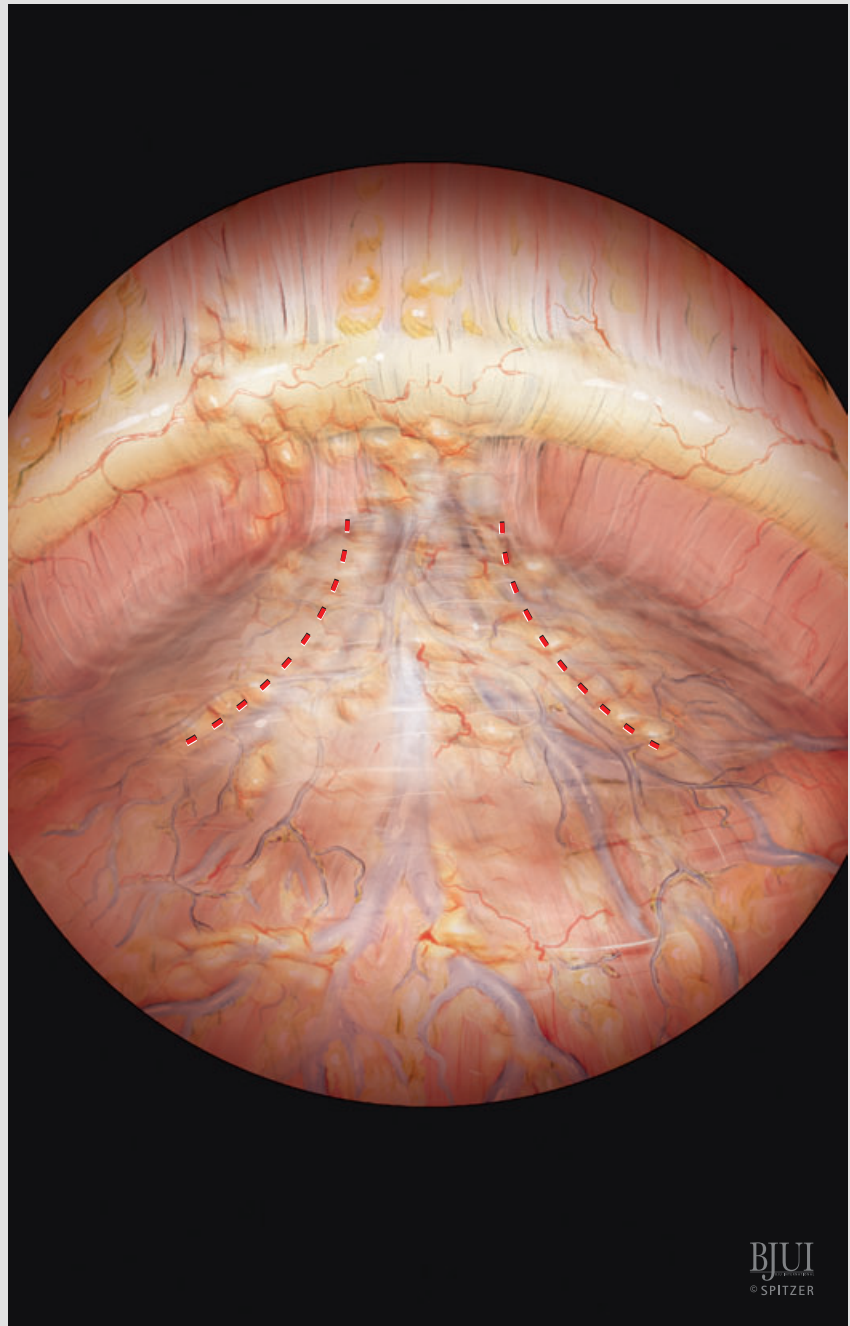


Figure 5

The levator muscle and, at the apex of the prostate, the puboperinealis muscle (Wilson's muscle) are dissected and swept laterally exposing the apex and the overlying dorsal vein complex. Sometimes a vessel travelling with the puboperinealis muscle perforates into the prostate, requiring clipping with a Hem-o-lok and sharp transection.

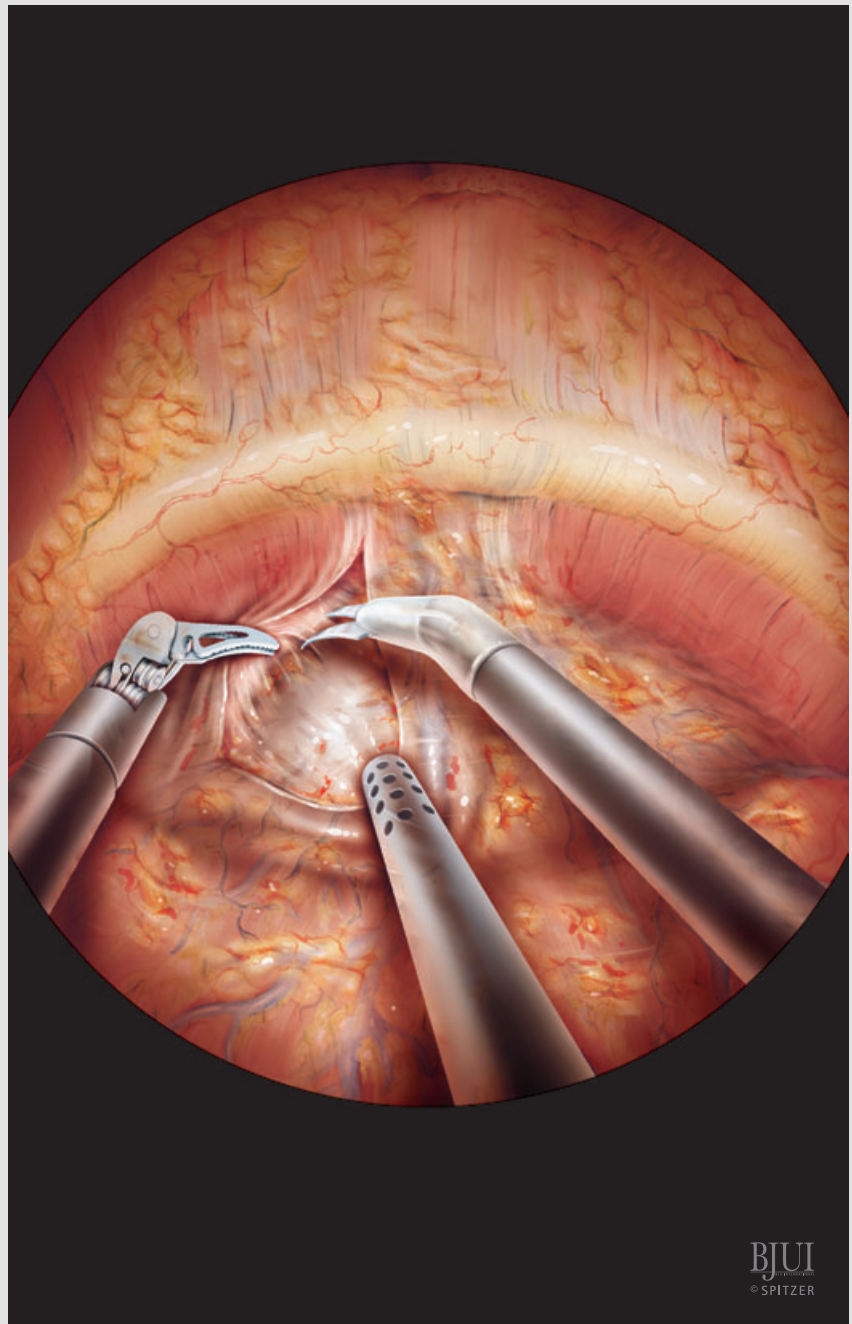
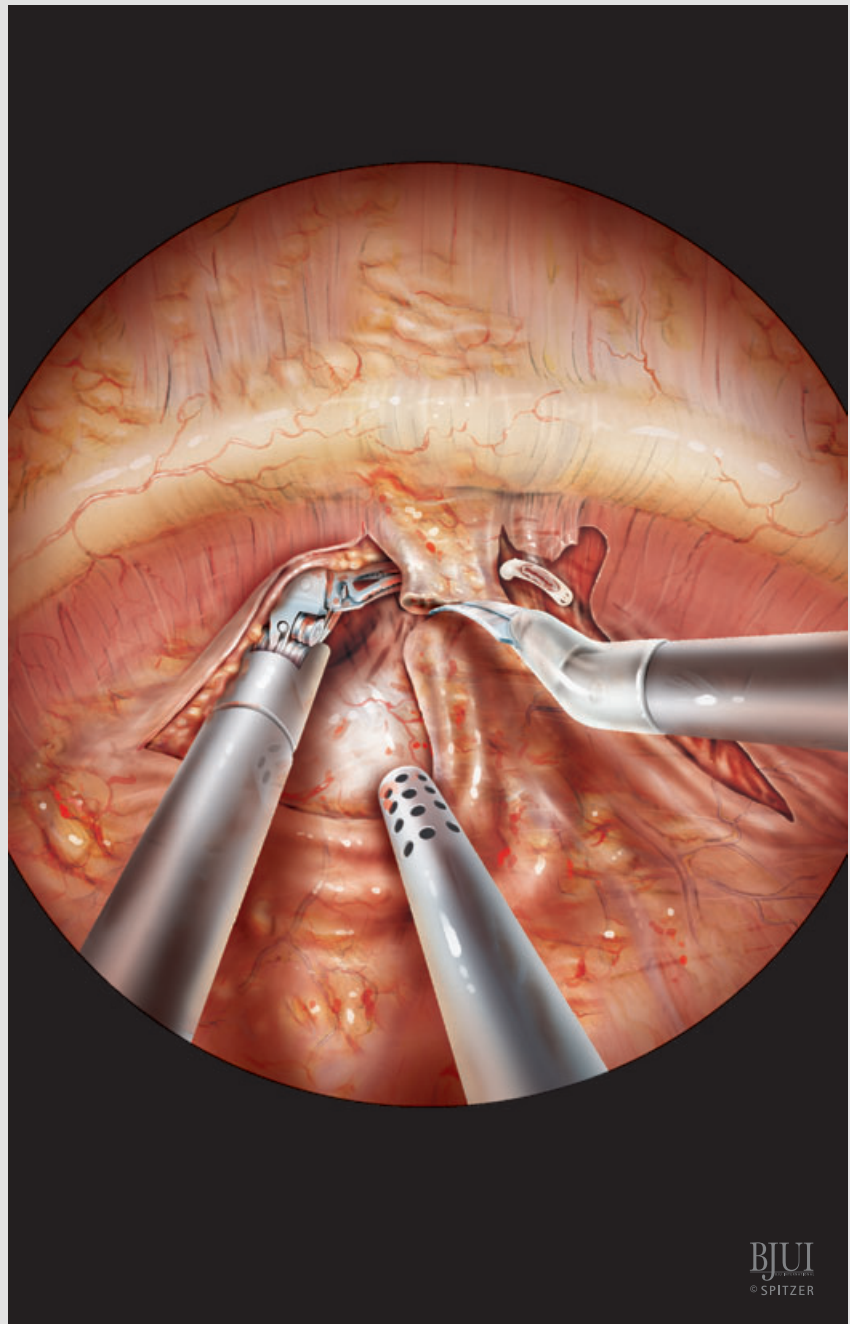


Figure 6

Once the periprostatic fascia has been separated on both sides and the apex of the prostate has been defined, the tissue overlying the urethra that contains the dorsal venous complex is transected, while the assistant pushes the prostate down.



GILLITZER *ET AL.*

Figure 7

If bleeding occurs after transection, which is uncommon due to the pneumoperitoneum, the edge of the transected dorsal vein complex is oversewn by a running suture using a 5/8 needle (UR-6) with a 3/0 braided suture.

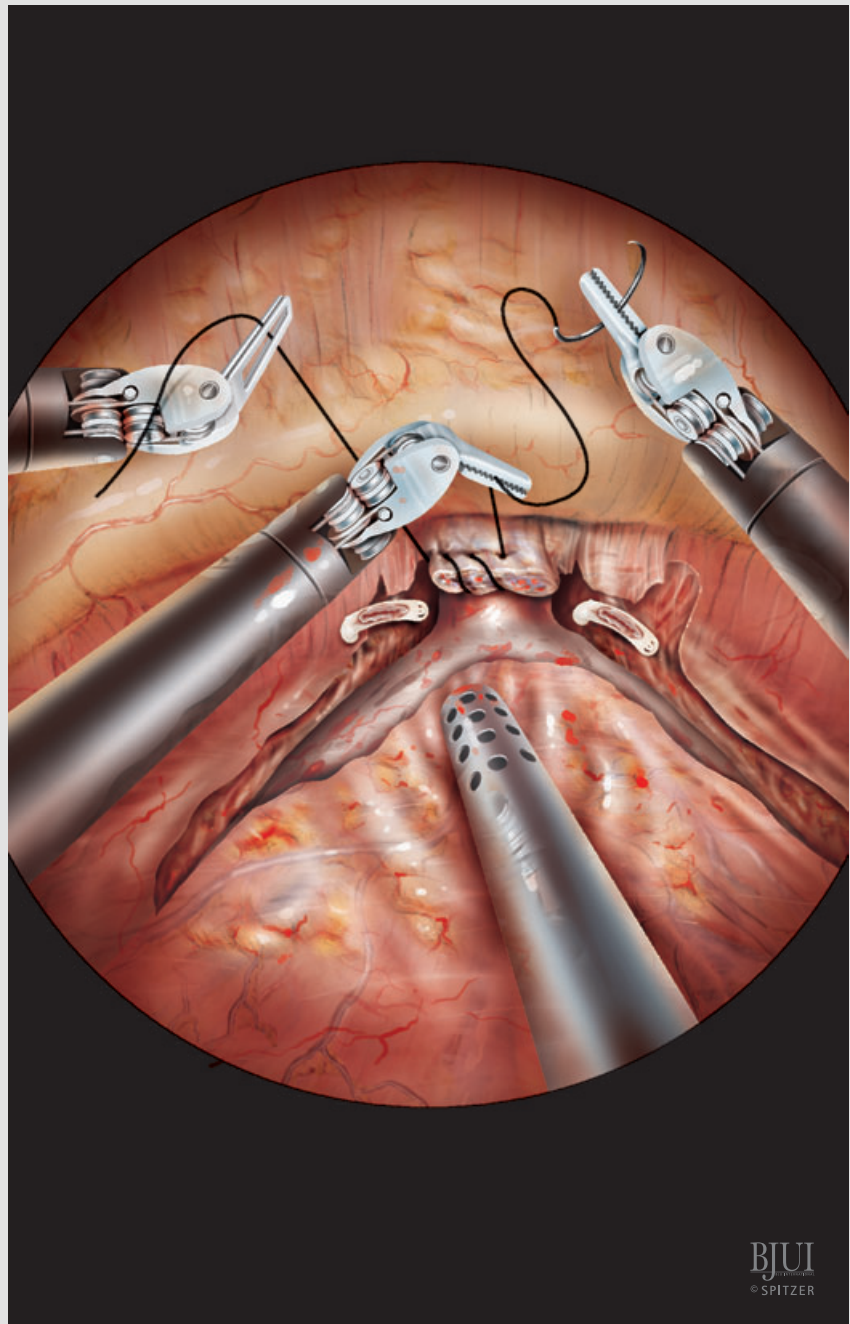
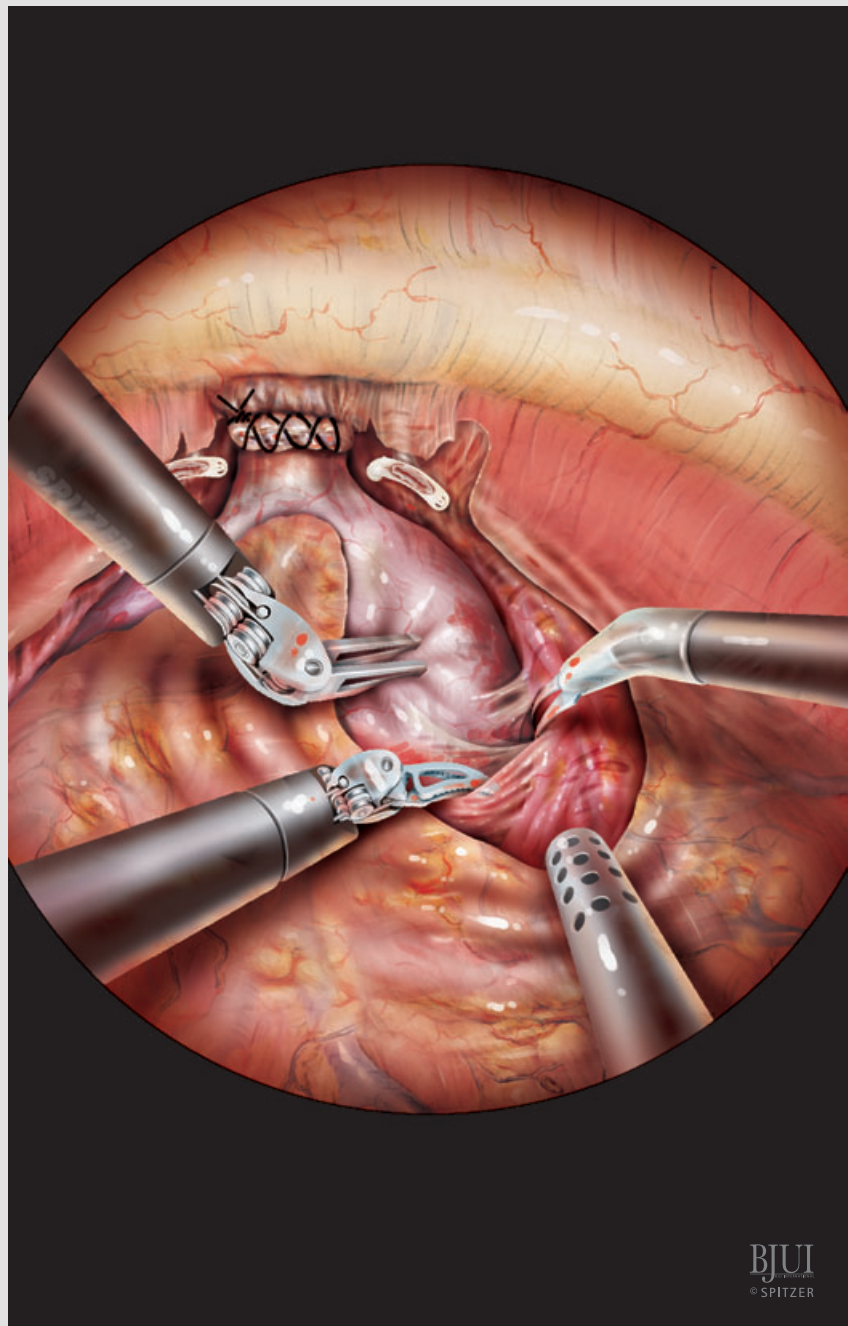


Figure 8

The periprostatic fascia containing sparse nerve fibres ventrally and the main NVBs dorsally is bluntly and sharply dissected from the prostatic capsule in an ascending manner starting from the apex towards the bladder neck.



BJUI
© SPITZER

Figure 9

The remaining procedure is performed in a descending manner. The transition between bladder neck and prostate can be outlined either by 'pinching' the bladder neck on both sides with the robotic instruments or by pulling up the bladder with the Prograsp (fourth arm) or with a grasper (assistant). Dissection of the bladder neck can be started from laterally or at the 12 o'clock position, depending on surgeon's preference.

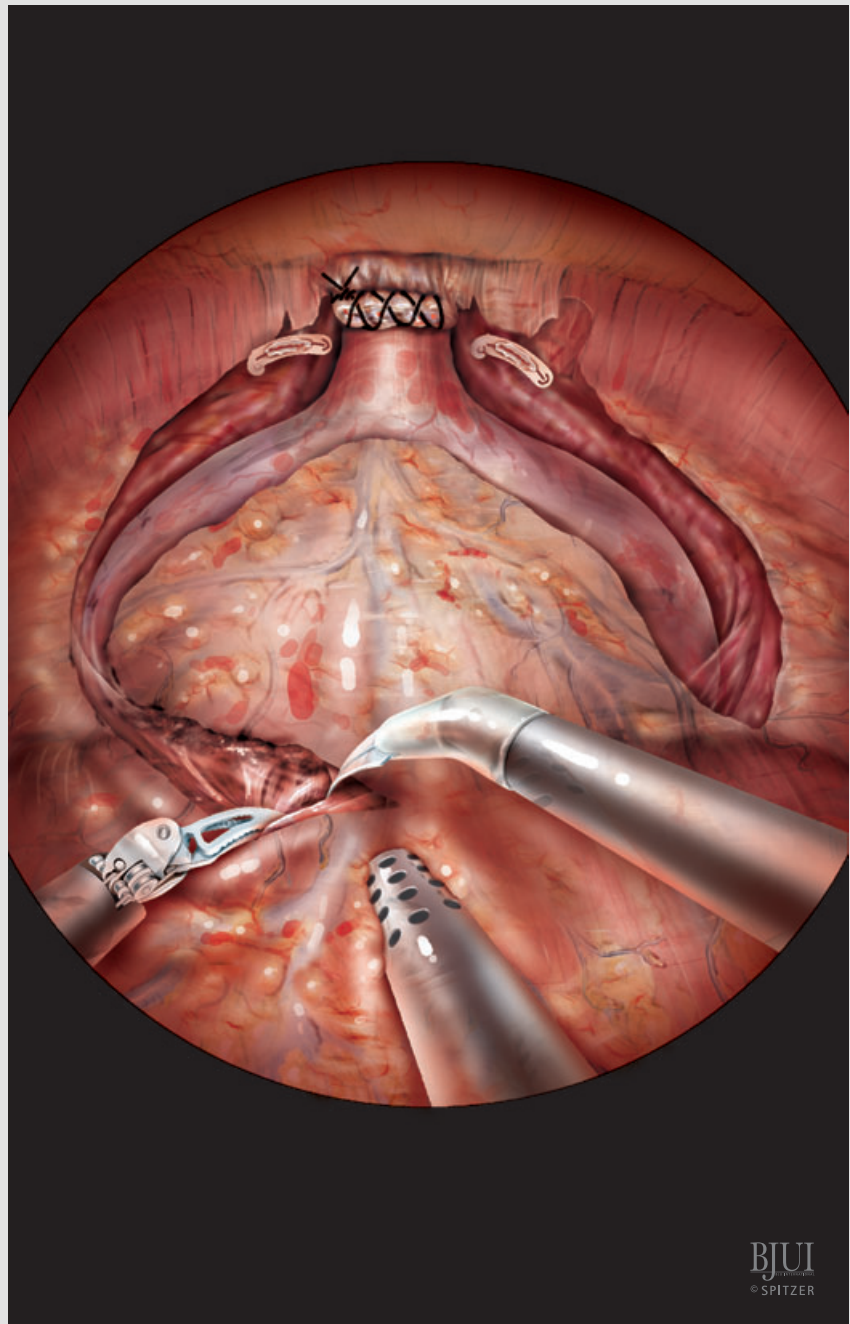


Figure 10

Once the ventral circumference of the bladder neck has been divided, the Foley catheter is deflated.

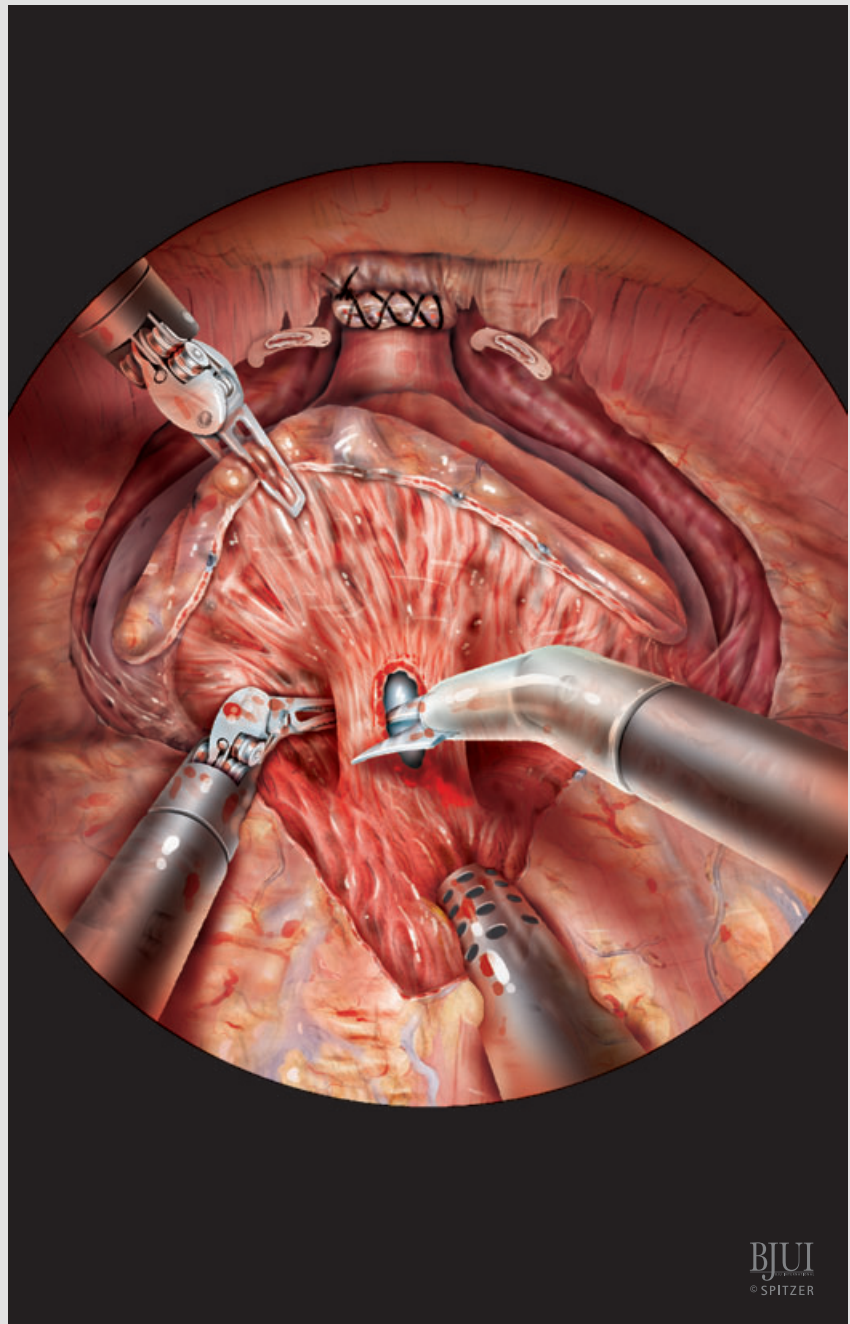


Figure 11

The tip of the Foley catheter is grasped with the fourth arm and pulled ventrally. The scrub nurse can now put the Foley catheter under tension by placing a cross clamp distal to the meatus. This manoeuvre will help to delineate the dorsal attachment of the trigone, which is still tethered to the prostate. Posterior transection of the dorsal circumference is straightforward, if there is no middle lobe. After transection of the dorsal circumference frozen-section biopsies from the bladder neck can be obtained. Sharp dissection now follows a more vertical course to cut the muscle fibres that still attach the bladder to the base of the prostate, opening the retrotrigonal space containing the seminal vesicles.

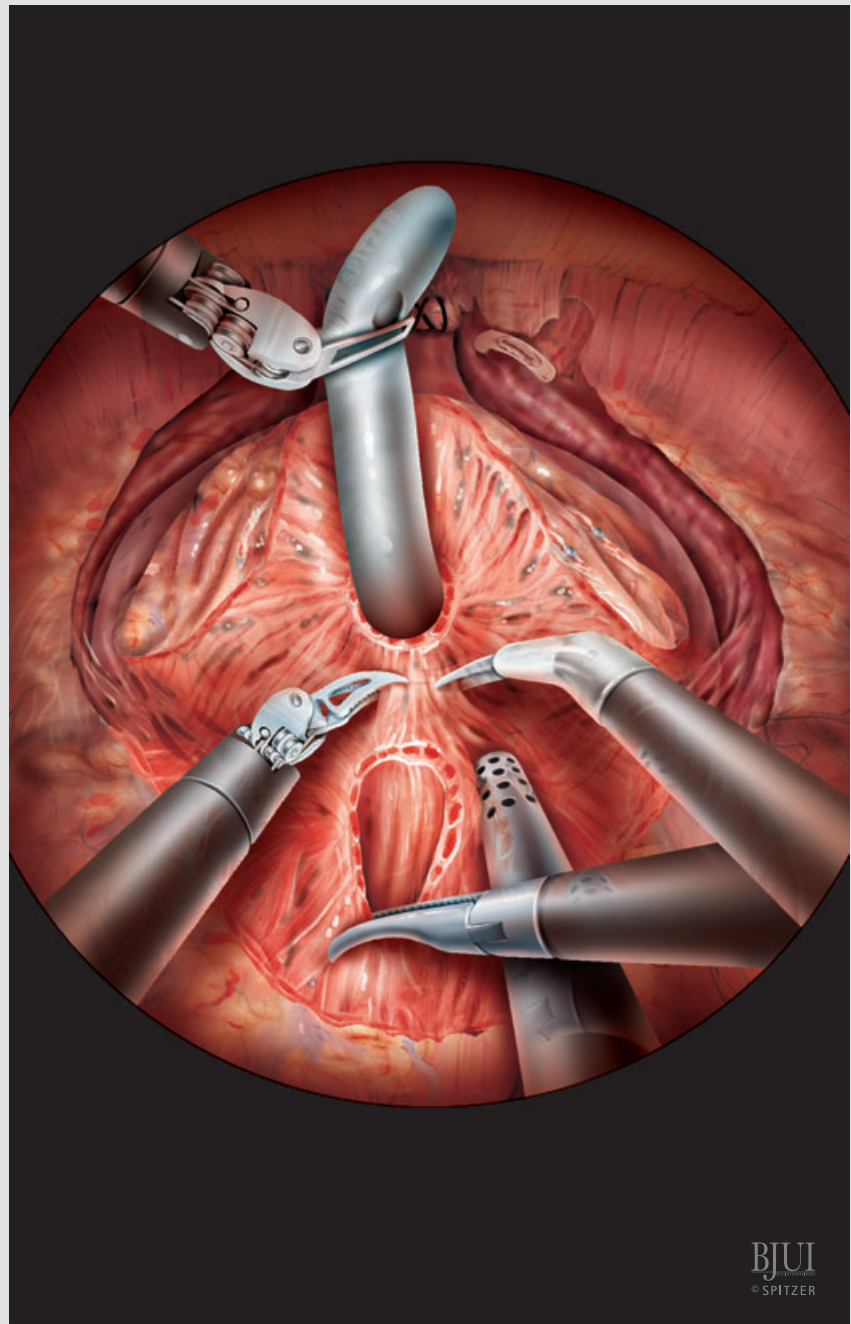


Figure 12

Usually dissection of the vas deferens and ipsilateral seminal vesicle can be done together, by dissecting between both vas deferens and elevating the vas with the corresponding seminal vesicle from medial, and proceeding with the dissection laterally. Simultaneously, the assistant pushes the bladder neck down. The fourth arm elevates the vas deferens and later the seminal vesicle. It is important to work dynamically with the fourth arm, repositioning it as dissection progresses.

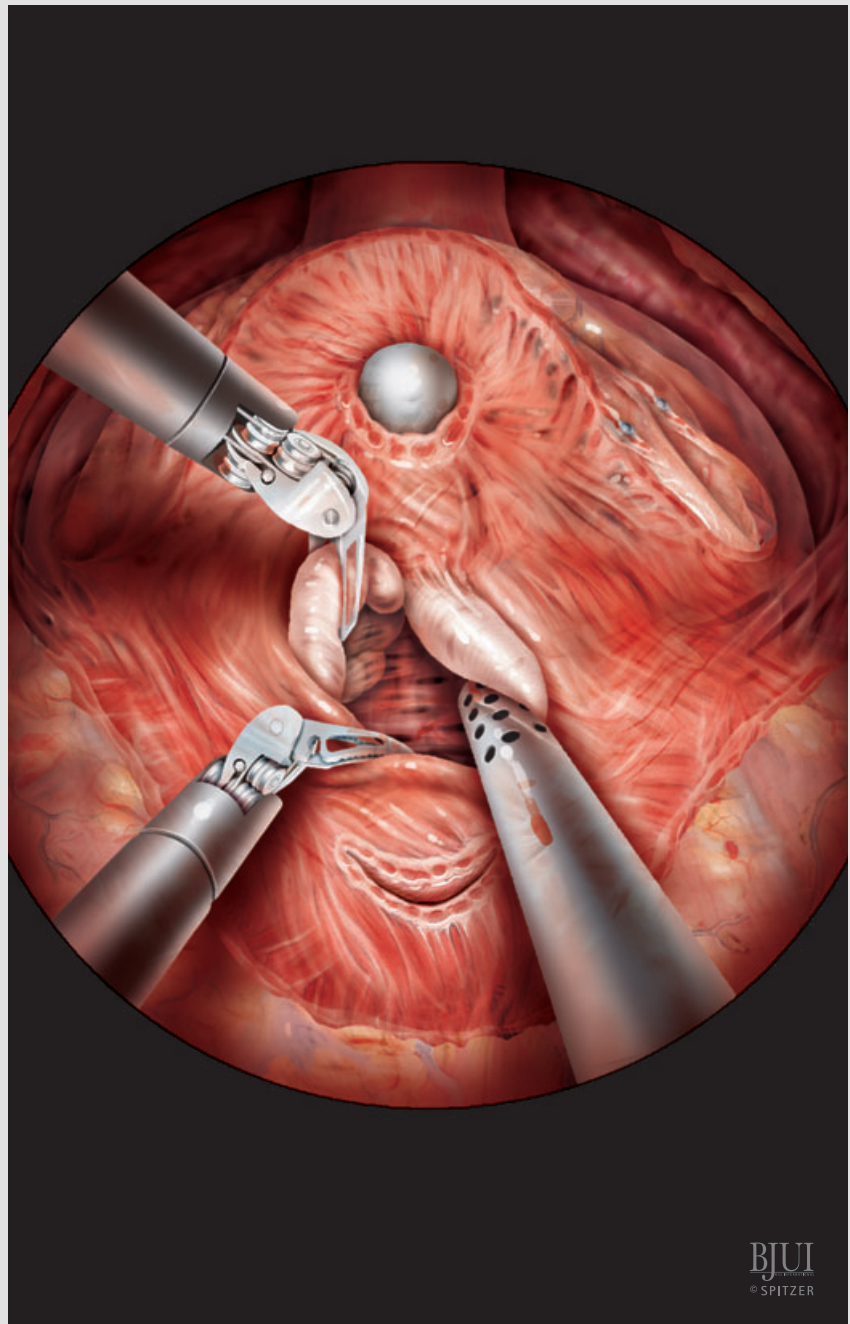


Figure 13

Once the vasa deferentia have been clipped and transected, dissection concentrates on the seminal vesicle. By grasping the seminal vesicle towards the contralateral side, its vessels can be identified running between the lobes of the seminal vesicles and along the lateral side.

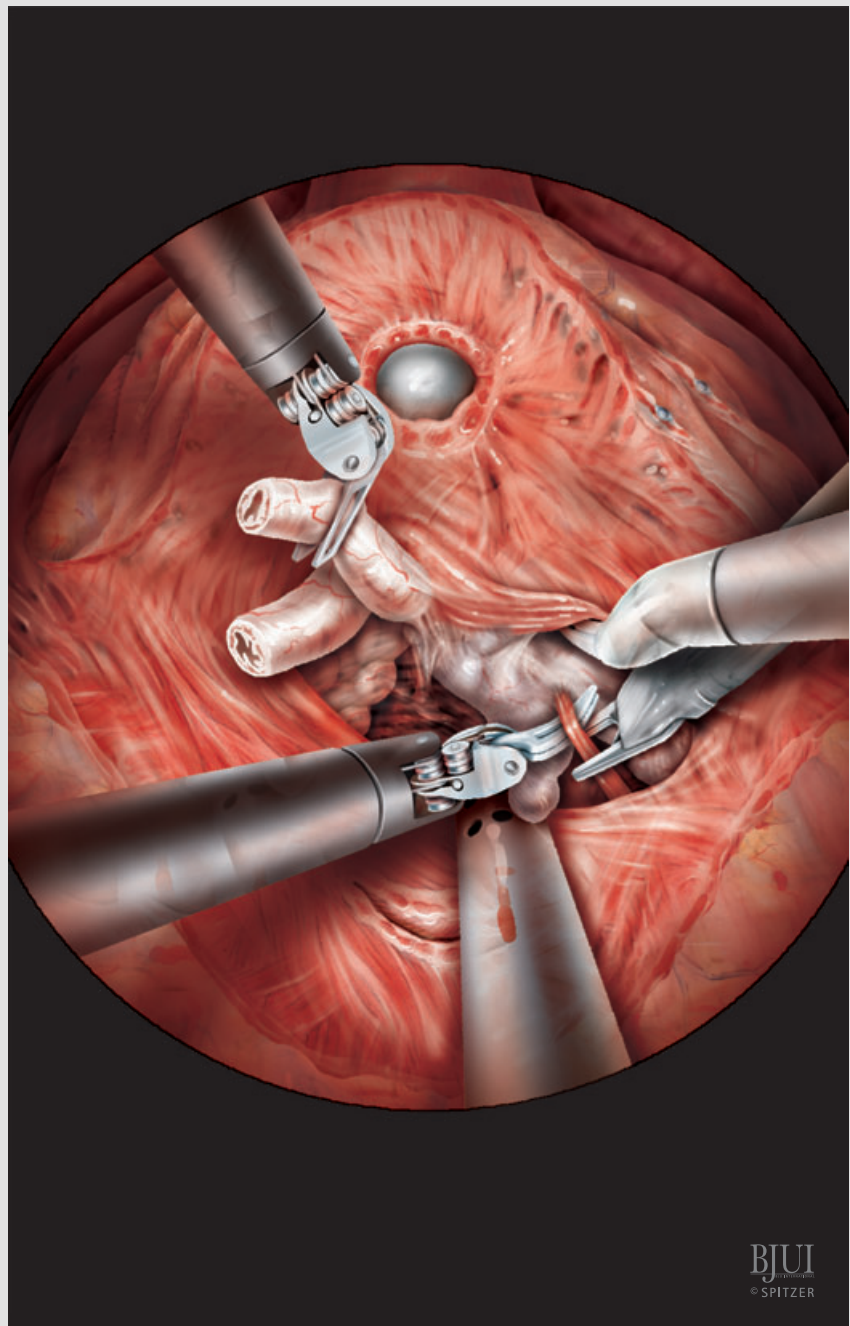
BJUI
© SPITZER

Figure 14

After the vessels between the lobes of the seminal vesicles have been clipped and transected, the seminal vesicle tip can usually be rolled up medially. Holding it with the fourth arm elevates the seminal vesicle vessels, which are clipped with small Hem-o-lok or metal clips. Bipolar coagulation at the level of the seminal vesicles must be avoided.

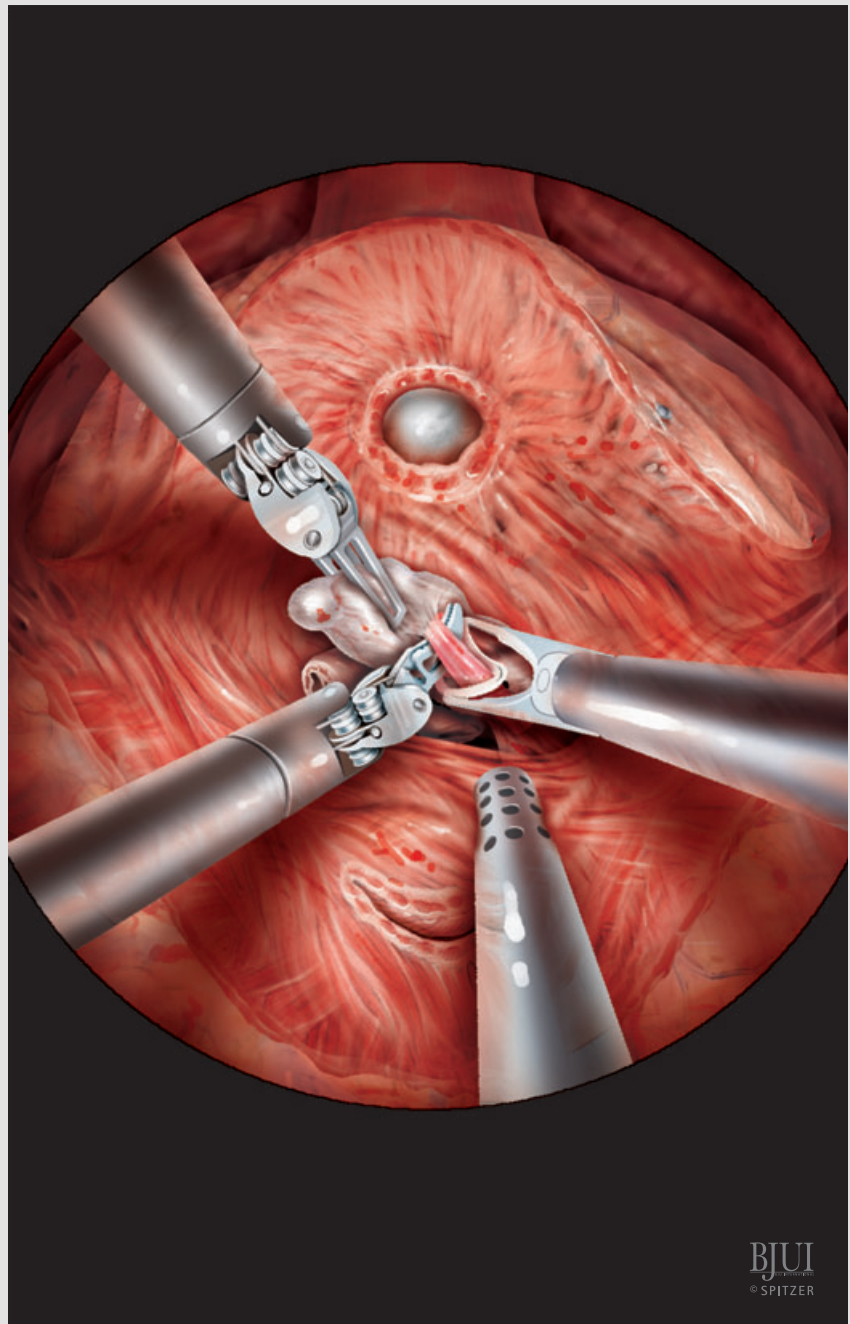


Figure 15

After completing the seminal vesicle dissection, Denonvilliers' fascia is stretched by holding up the left seminal vesicle and vas with the fourth arm, while the assistant holds up the right side. Denonvilliers' fascia is then cut transversally close to the prostate to enter the perirectal space. The rectum is dissected off the prostate towards the apex.

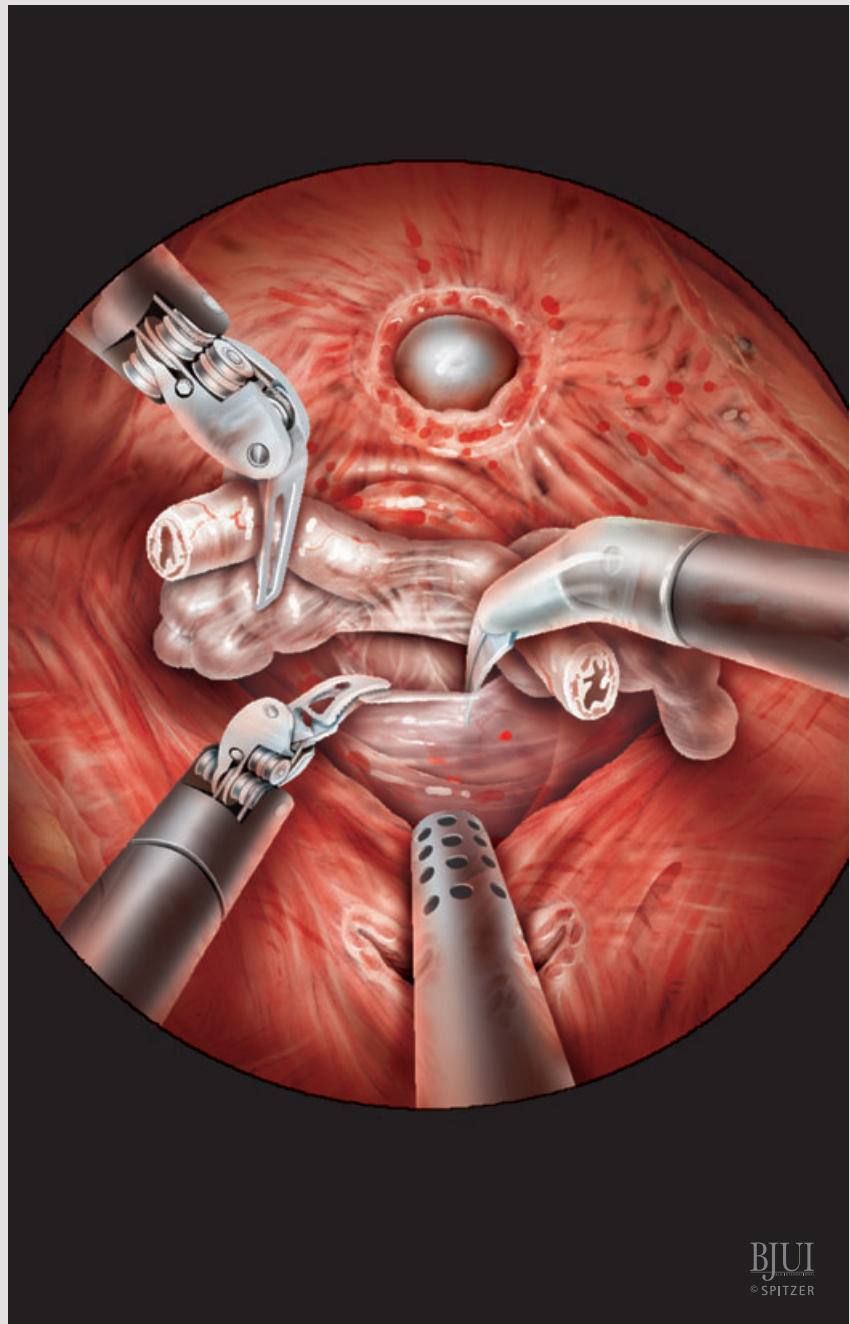


Figure 16

Separation of the periprostatic fascia with the NVBs from the prostate capsule is facilitated by ascending preparation of the prostatic pedicles, to proceed in a descending manner from the base of the prostate. Perforating vessels are laterally clipped by Hem-o-lok or metal clips and transected at their entry into the prostate capsule. The ipsilateral seminal vesicle is pulled to the other side. This is accomplished with the fourth arm to dissect the NVB and prostatic pedicles on the right side, and by the assistant for dissection on the left side.

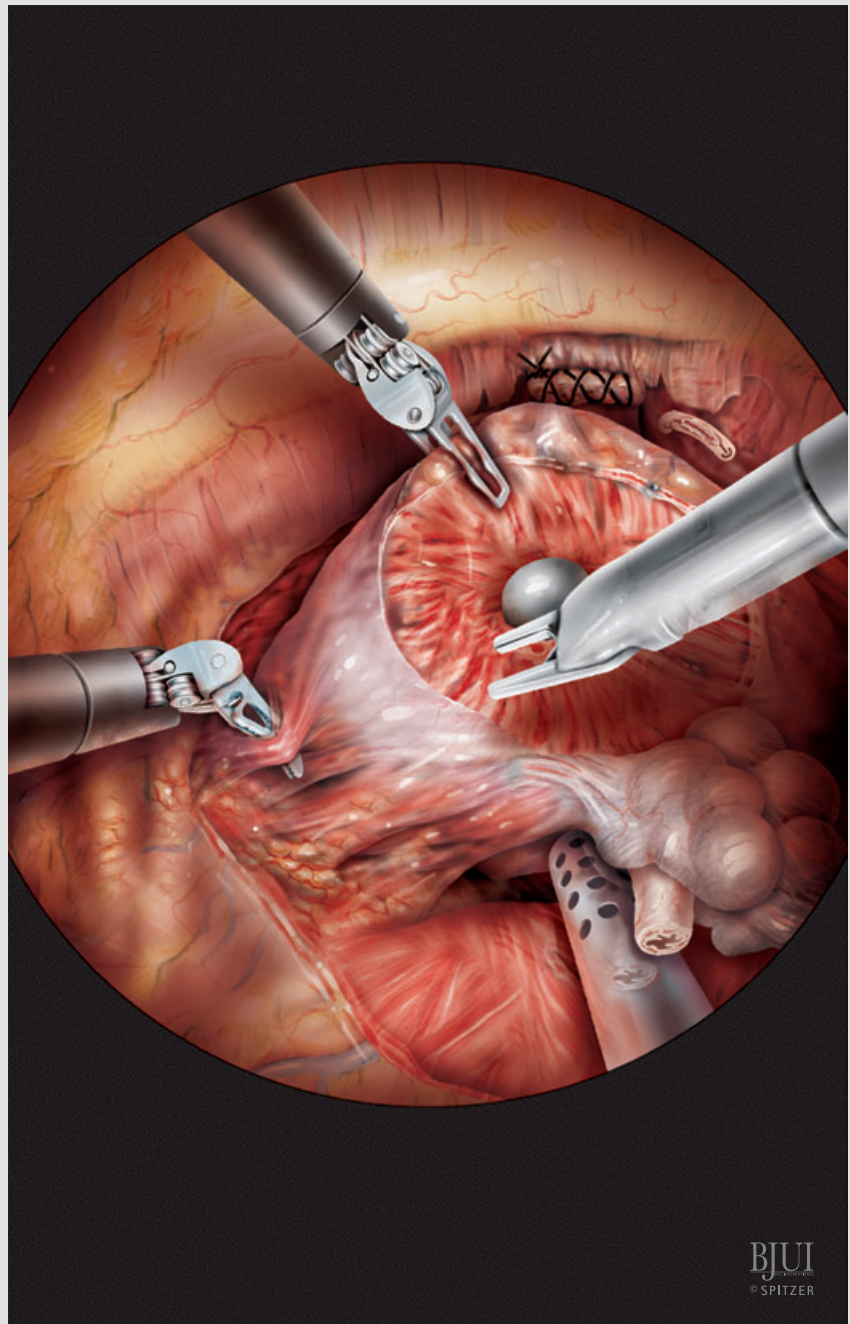
BJUI
© SPITZER

Figure 17

The prostatic pedicles are identified and vessels are separated by radial dissection with the Maryland grasper, then peripherally clipped and transected near to the prostate. As dissection progresses towards the apex, the fourth arm is repeatedly repositioned to put traction on the prostate and allow separation of the NVBs.

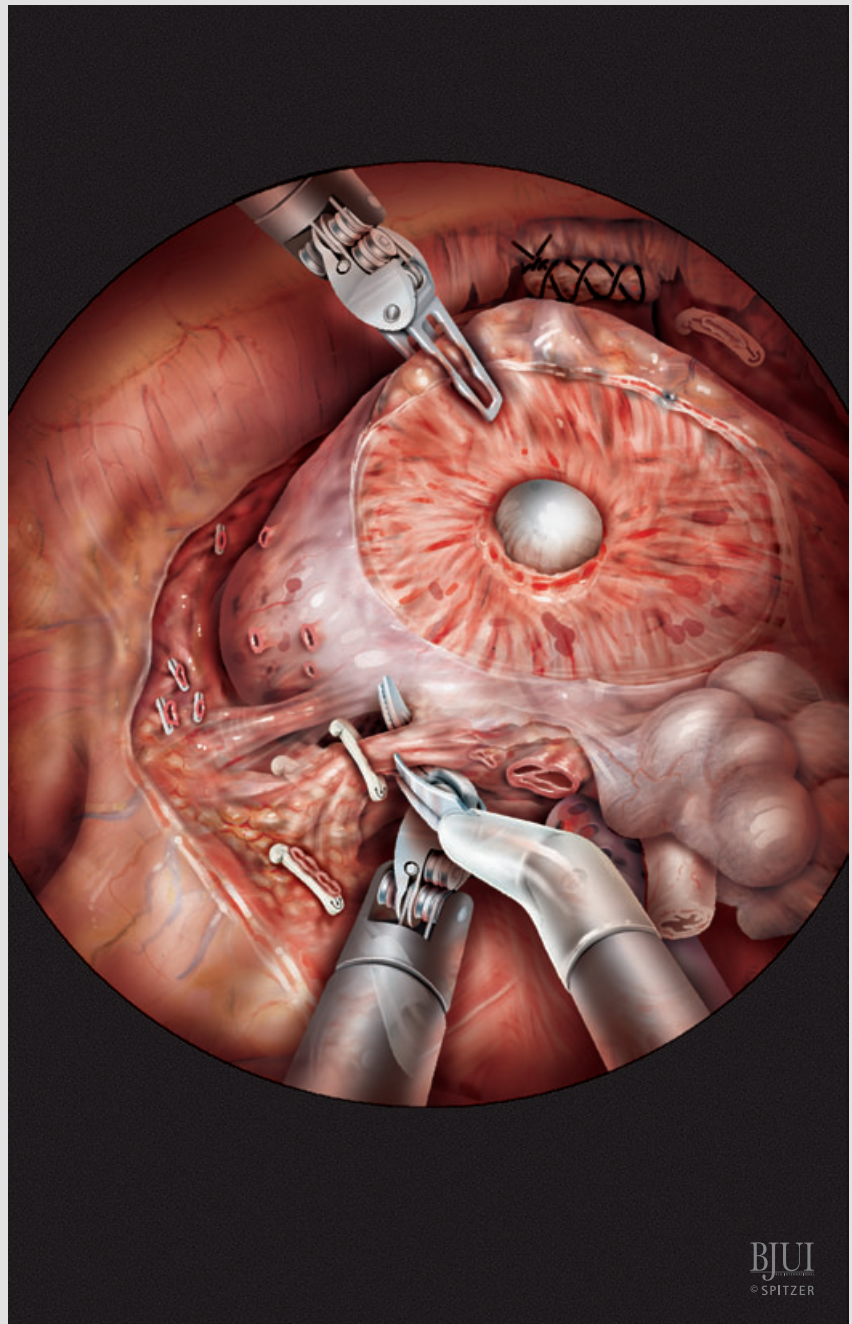


Figure 18

Once dissection at the base of the prostate has been completed, the NVBs can usually be simply swept away in a dorsal direction. Small vessels perforating into the prostate are clipped and divided. Dissection continues towards the apex of the prostate. As mobility of the prostate increases, it can be rotated with the fourth arm to allow for a more dorsal dissection. At the level of the urethra, the rectourethralis muscle attachment to the apex of the prostate is transected.

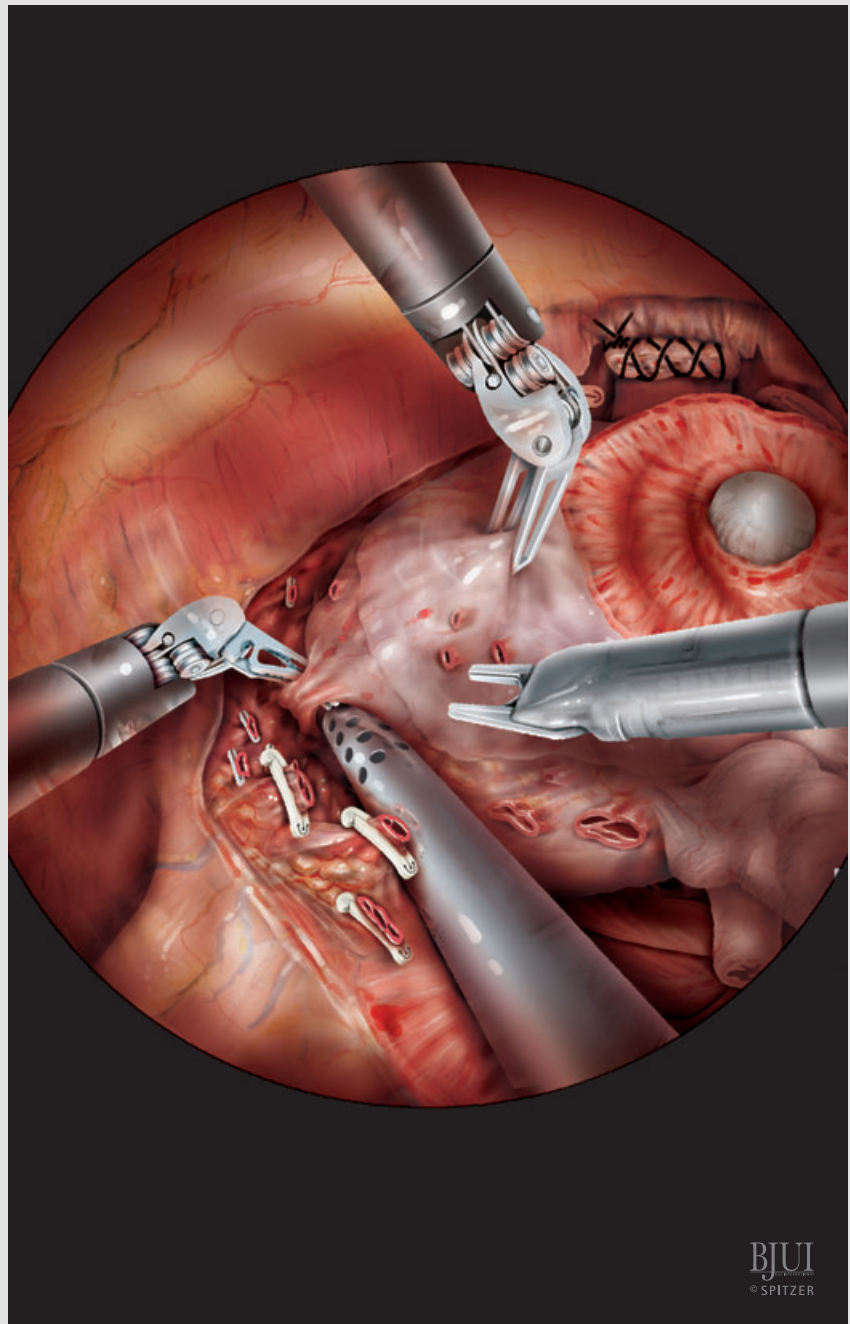


Figure 19

After the prostate has been completely mobilized and the rectourethralis muscle transected, the prostate is put on traction in a cephalad and dorsal direction, and the ventral circumference of the urethra is incised. The tip of the Foley catheter is used as a reference to view and incise the dorsal circumference.

After detaching the prostate, it is placed in a specimen bag brought through the 12-mm assistant trocar. The bag-closing string can be left running through the port or the port can be replaced parallel to the suture, if gas excessively escapes through the port or if the assistant's instruments get entangled with the string of the specimen bag.

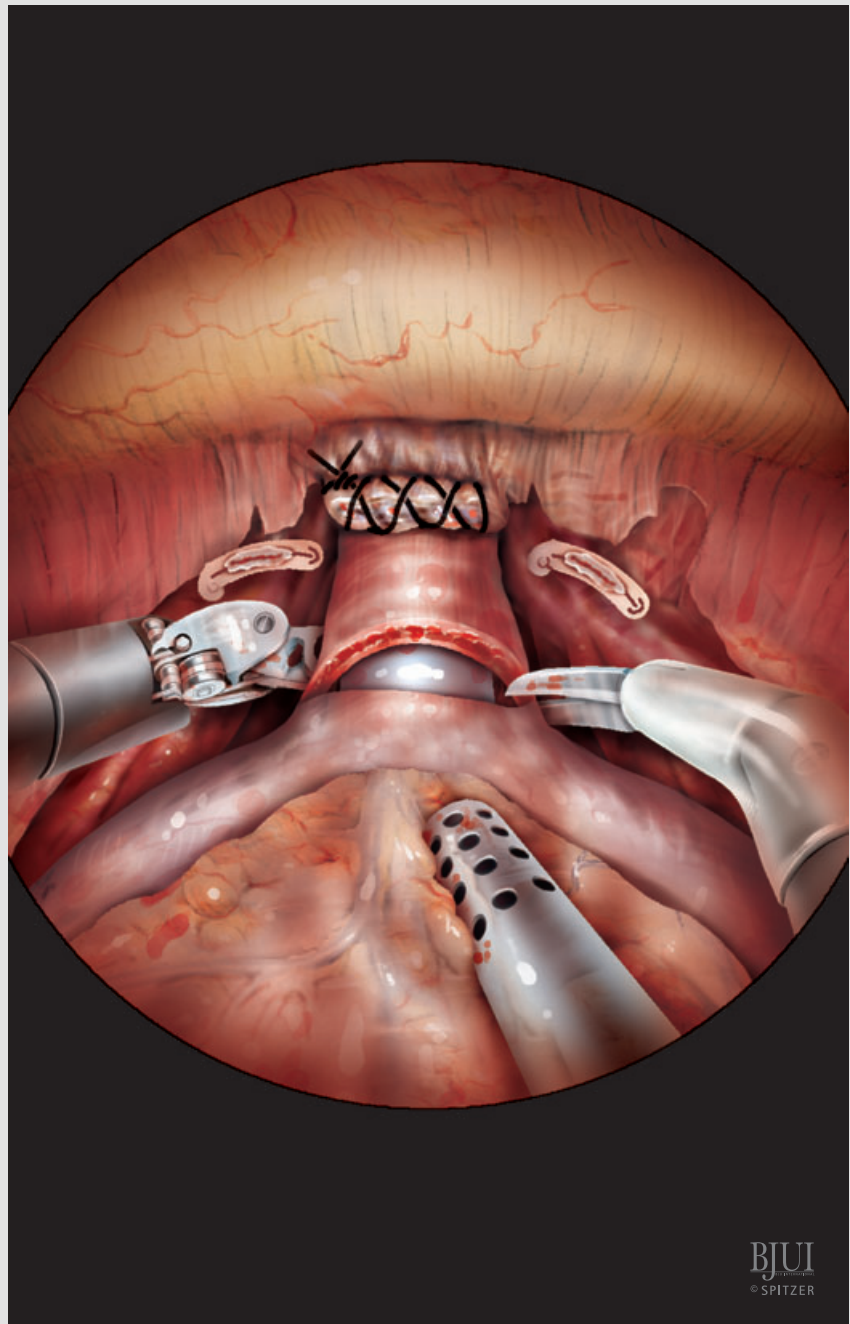


Figure 20

For posterior reconstruction, the rectourethralis muscle is readapted to the transected retrotrigonal muscle layer with a 2/0 continuous monofilament suture armed with a Lapra-Ty clip at the end. After pulling the suture tight, it is secured with another Lapra-Ty clip.

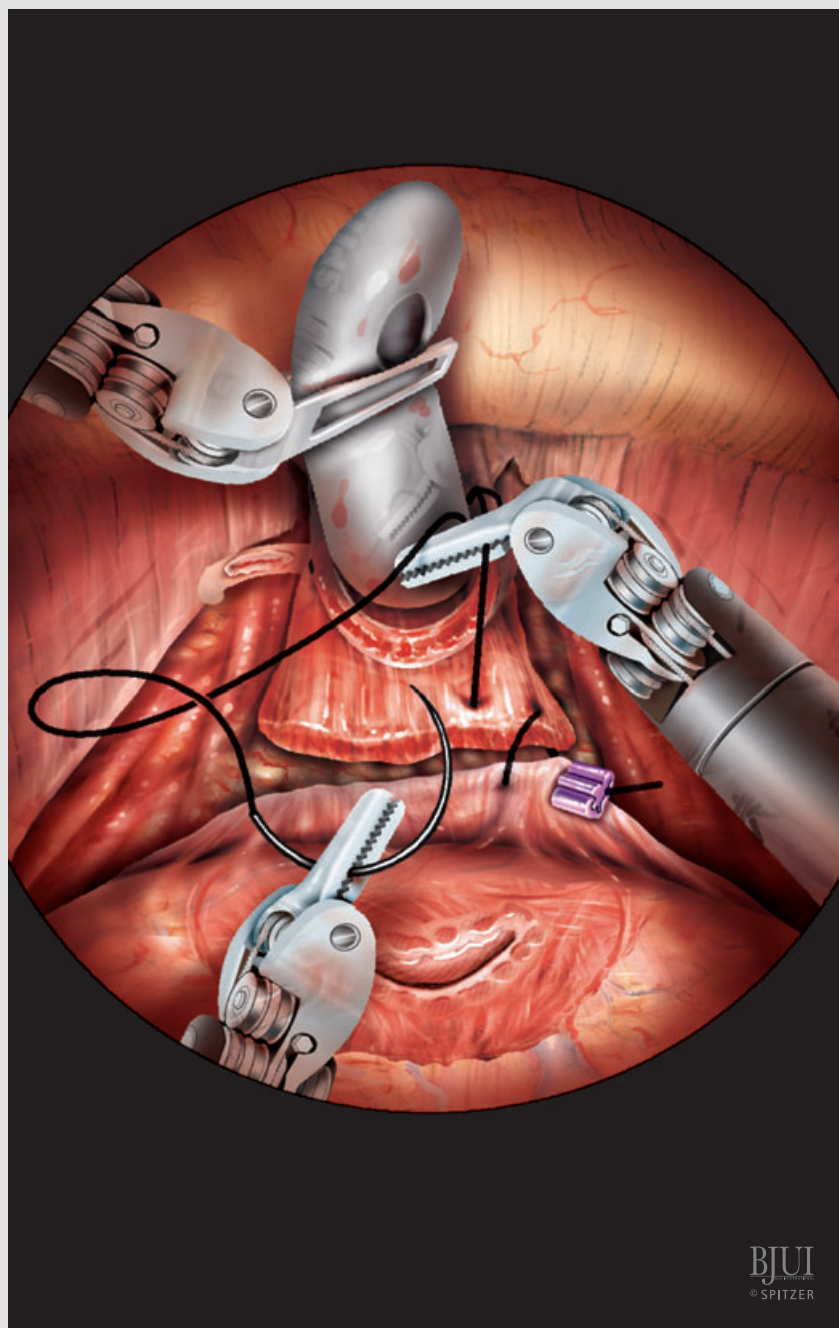


Figure 21

The vesicourethral anastomosis is completed by using two different 2/0 monofilament sutures on a 5/8 needle (UR-6) cut to 20 cm long, each armed with a Lapra-Ty clip at the end, and joined together by a Hem-o-lok clip that acts as a bolster. The first stitch is placed at the 6 o'clock position on the urethra (outside to inside) and then at the 6 o'clock position on the bladder (inside to outside), and run continuously in a 'parachute' technique along the dorsal circumference on both sides. For ease of the outside-in stitches in the urethral stump, a curved Lowsley retractor is inserted into the urethral stump and directed by the assistant. After placing about five tight stitches, the suture is pulled tight and anchored with a Lapra-Ty clip on the bladder side. This step is critical for dispersing the tension force on the suture line and thus preventing tearing of the suture through the tissues. The same procedure is done with the second suture locked to the Hem-o-lock on the opposite side of the anastomosis.

Both suture lines are continued ventrally and a Foley catheter is newly inserted before the anastomosis is completed, and blocked afterwards with 30 mL. Both sutures are continued until the ends meet approximately at the 12 o'clock position on the bladder side and are knotted. The anastomosis is checked for watertightness with 100–200 mL saline filled into the bladder.

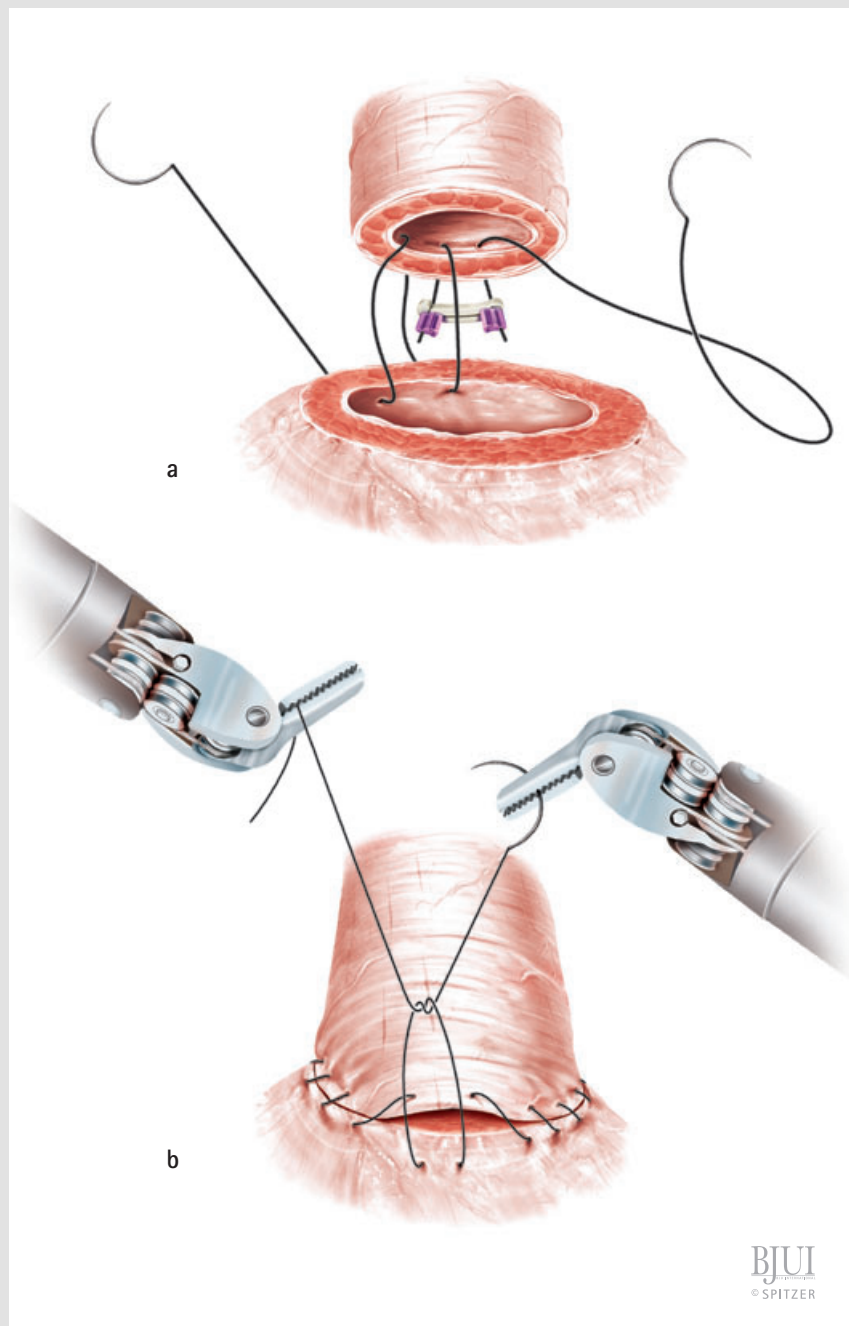
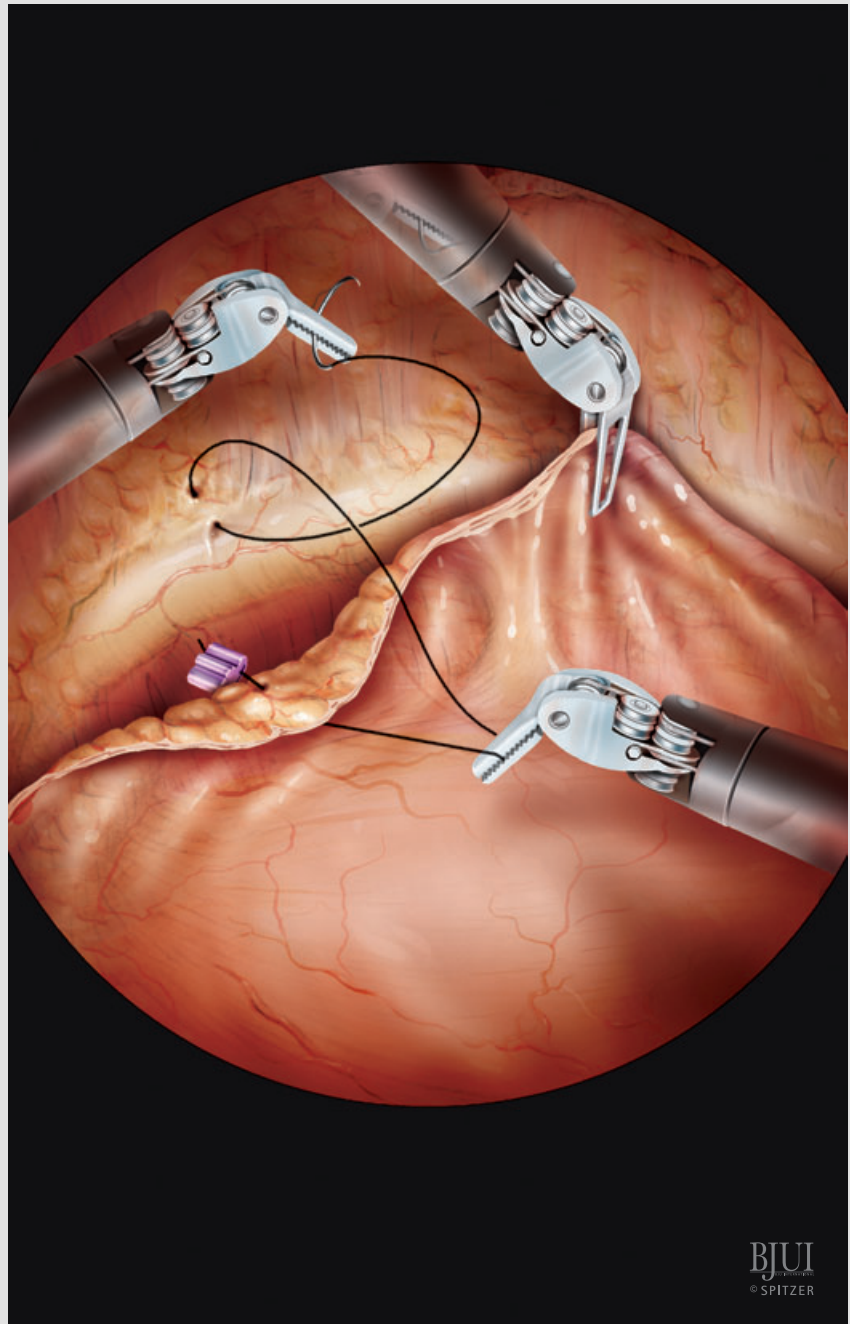


Figure 22

We readapt the peritoneal margin of the bladder with the lateral peritoneal margin over the iliac vessels by using two running monofilic sutures armed with a Lapra-Ty clip (one for each side). The suture line is continued medially to readapt the peritoneal margin with the anterior abdominal wall above the pubic symphysis. The sutures can be locked intermittently with Lapra-Ty clips every other stitch. A 20 F drain is introduced through the fourth arm trocar and placed in a paravesical position. The endoclose is used to prepare a ligature at the 12-mm assistant port, which is tied at the end of the procedure.

After decoupling the da Vinci robotic cart from the ports, the end of the specimen bag string is exteriorized with a grasper through the paraumbilical optic trocar. The trocars are removed and the specimen bag is retrieved by enlarging the paraumbilical incision adapting to the prostate size. The incision is closed in one layer.



BJUI
© SPITZER

POSTOPERATIVE CARE

On the day of the procedure the patient is kept on parenteral fluids. A third-generation cephalosporin and non-opiate analgesics are administered with i.v. fluids. Thrombosis prophylaxis is administered as s.c. heparin.

On the first day after RALP the patient receives a laxative and is started on a liquid diet. Regular diet is offered after the first bowel movement. The patient is encouraged to ambulate on the first day.

The paravesical drain is removed 2–3 days after surgery, depending on drainage output. A clear drain output on the day after surgery is usually elevated due to the use of irrigation fluid during the procedure.

If the bladder neck was not reconstructed and anastomotic leakage was excluded during surgery, a cystogram is taken at 5 days after RALP. Otherwise, we take a cystogram at 7 days before removing the Foley catheter.

FROM SURGEON TO SURGEON

THINGS TO MAKE LIFE EASIER

The importance of obtaining adequate patient cushioning cannot be stressed enough. The whole body of the patient rests on his shoulders, and at the beginning of the surgical experience, this can be over a considerably long period. Alternatively, the patient can be set on a vacuum device similar to those used for trauma patients.

At the beginning of the surgeon's experience it is important to have the same team working together. An experienced assistant is essential for progress of the procedure. It takes some time for the assistant to instinctively find the correct way for intra-abdominal instrument manipulation without collision with the other instruments or hindrance to the surgeon. Previous laparoscopic experience is helpful in this respect.

Mark the position of the working parts on the skin after insufflation, since distances will vary considerably. It is very important for the assistant to rely more on irrigation than suction during dissection of the dorsal vein complex and preparation of the NVBs. Irrigation will clean the operative field, increasing visualization of structures. Suction

is counterproductive in as much as it will increase bleeding from venous sinuses by reducing intra-abdominal pressure. If bleeding is profuse during transection of the dorsal vein complex and visualization is impaired, intra-abdominal pressure can be increased temporarily to 20 mmHg.

If pelvic lymphadenectomy is indicated, it is recommended to insert the lateral trocars (12 mm assistant trocar and fourth arm robotic trocar) 1–2 cm more medial, to avoid collision with the pelvic rim.

The 5- and 12-mm assistant ports can be interchanged at the surgeon's choice. Having the 12-mm port placed more medially (i.e. in position of the 5-mm port) improves the angle of action for the clip applier, especially when dissecting the NVB. As a disadvantage, the retrieval of needles cannot be monitored with the camera as precisely as in a lateral position.

When performing surgery on obese patients with a body mass index of $>32 \text{ kg/m}^2$ it is advisable to use longer robotic trocars and insert the trocars in a strict perpendicular direction.

Large prostate glands are not a contraindication at the beginning of the RALP experience. Visualization of the bladder neck is frequently improved by a large gland, and reconstruction of the bladder neck does not require specific manoeuvres.

Definition of the transition from the prostate to the bladder can be improved by bilateral 'pinching' of the bladder with the robotic arms. The loosely attached bladder will indent at its junction with the prostate.

A 2/0 'package' suture that takes the endopelvic fascia borders on the ventral prostatic surface and is held with the fourth arm can be used alternatively for dissection of the bladder neck. This suture will also prevent back-bleeding from the prostate.

Using a stiff silicon catheter to grasp with the fourth arm for elevation of the prostate during transection of the dorsal circumference of the bladder neck gives better tension than with a latex catheter.

The bladder neck can be reconstructed ventrally or dorsally with interrupted or continuous sutures in a tennis-racket form.

We recommend reconstruction of the bladder neck in an inverted Y-fashion if the ureteric orifices are close to the resection margin. Protective intraoperative insertion of a JJ stent can be done easily through the 12-mm assistant port.

A Lowseley retractor can direct the urethra and facilitate visualization and placement of the urethral stitches during the vesicourethral anastomosis.

In case pelvic lymphadenectomy has been performed, readaptation of the peritoneal margin of the bladder to the abdominal wall at the end of the procedure should not include the lateral peritoneal margin over the iliac vessels, as this can lead to lymphocele formation.

We prefer to place a 20 F silicon three-way catheter to allow for postoperative continuous irrigation in case of haematuria. We always advise placing an intra-abdominal drain. It will not only drain the irrigation fluid used during the procedure, but allows also reliable monitoring for postoperative haemorrhage.

Surgery can also be performed with only one needle holder and the Maryland bipolar grasper, to reduce consumable costs. However, suturing with the Maryland grasper, which has a low grasping force, is far more difficult than with a needle driver.

REFERENCES

- 1 **Binder J, Kramer W.** Point of Technique. Robotically-assisted laparoscopic radical prostatectomy. *BJU Int* 2001; **87**: 408–10
- 2 **Berryhill R, Jhaveri J, Yadav R et al.** Robotic prostatectomy: a review of outcomes compared with laparoscopic and open approaches. *Urology* 2008; **72**: 15–23
- 3 **Patel VR, Palmer KJ, Coughlin G, Samavedi S.** Robot-assisted laparoscopic radical prostatectomy. perioperative outcomes of 1500 cases. *J Endourol* 2008; **22**: 2299–305
- 4 **Shrivastava A, Baliga M, Menon M.** The Vattikuti Institute prostatectomy. *BJU Int* 2007; **99**: 1173–89
- 5 **Mattei A, Naspro R, Annino F et al.** Tension free and energy-free robotic-assisted laparoscopic radical

- prostatectomy with interfascial dissection of the neurovascular bundles. *Eur Urol* 2007; **52**: 687–95
- 6 **Tewari AK, Bigelow K, Rao S *et al.*** Anatomic restoration technique of continence mechanism and preservation of puboprostatic collar: a novel modification to achieve early urinary continence in men undergoing robotic prostatectomy. *Urology* 2007; **69**: 726–31
- 7 **Tewari A, El-Hakim A, Rao S, Raman JD.** Identification of the retrotrigonal layer as a key anatomical landmark during robotically assisted radical prostatectomy. *BJU Int* 2006; **98**: 829–32
- 8 **Walsh PC, Marschke P, Ricker D, Burnett AL.** Use of intraoperative video documentation to improve sexual function after radical retropubic prostatectomy. *Urology* 2000; **55**: 62–7
- 9 **Rassweiler J, Wagner AA, Moazin M *et al.*** Anatomic nerve-sparing laparoscopic radical prostatectomy. comparison of retrograde and antegrade techniques. *Urology* 2006; **68**: 587–92
- 10 **Van Velthoven RF, Ahlering TE, Peltier A, Skarecky DW, Clayman RV.** Technique for laparoscopic running urethrovesical anastomosis: the single knot method. *Urology* 2003; **61**: 699–702
- Correspondence: Rolf Gillitzer, Department of Urology, University Medical Center Mainz, Johannes Gutenberg University, Langenbeckstr. 1, 55131 Mainz, Germany. e-mail: gillitze@mail.uni-mainz.de
- Abbreviations: **RALP**, robot-assisted laparoscopic radical prostatectomy; **RP**, retropubic radical prostatectomy; **NVB**, neurovascular bundle.